

Radiation Therapy to Prevent Coronary Artery Restenosis

*“Issues surrounding the use of radiation for treatment
of cardiac diseases, clinical results, the role of the
radiation oncologist, the future of IVBT”*

Ian Crocker MD
Associate Professor of Radiation Oncology
Emory University School of Medicine
Atlanta, Georgia

I. Background

Restenosis remains the limiting factor of percutaneous transluminal coronary angioplasty (PTCA).¹⁻³ Renarrowing of the vessel may occur as a result of vascular recoil, neointimal hyperplasia or negative remodeling (contracture) of the vessel. Clinical trials of a variety of pharmacologic agents⁴⁻⁷ have met with little success. Of the mechanical means of angioplasty (atherectomy, laser and stenting) only intracoronary stenting has resulted in superior results to balloon angioplasty.^{8,9, 10, 11} However, as the indications for stenting have broadened the likelihood of restenosis has increased.¹² Longer lesions, smaller vessels, poor run-off, diabetes and other comorbid conditions have been associated with unacceptably high rates of restenosis. The gradual development of the concept that restenosis was the end-result of an uncontrolled proliferation of tissue at the injury site laid the groundwork for radiation being tested in this area.^{13, 14, 15, 16} In vitro studies had demonstrated the inhibition of proliferation of arterial smooth muscle cells (SMC's) and fibroblasts as well as decreased collagen synthesis by fibroblasts.^{17, 18, 19} The development of the porcine overstretch balloon injury model of restenosis has provided an excellent model in which to evaluate new therapies since as radiation.²⁰ In this animal model one or more of the coronary vessels are subjected to overstretch balloon injury and at two weeks, four weeks or six months the animal is sacrificed and the vessels harvested. Morphometric or immunohistochemical measurements are then undertaken to assess the efficacy of the intervention on the vascular healing response.

The different radiation techniques to prevent restenosis can be considered within a few broad categories: 1. External techniques and 2. Endovascular techniques. In the

endovascular therapies we need to consider both temporary implants (catheter based techniques) and permanent implants (radioactive stents). I have arbitrarily divided the catheter based therapies into beta and gamma systems although they could as easily have been considered as sealed source and non-sealed source therapies.

In the following sections we shall discuss the current status of vascular radiotherapy from both preclinical and clinical perspectives.

II. Preclinical Studies of Coronary Radiotherapy

a. External Radiation Studies

The potential advantages of external beam irradiation over endovascular approaches include 1) No additional cath lab time to deliver treatment 2) No costs of disposables such as are associated with the new endovascular delivery systems 3) Ability to optimize the timing of the treatment in relationship to the intervention 4) The ability to delivery fractionated therapy which may be associated with fewer late effects and 5) The delivery of a much more homogeneous dose to the vessel wall.

The results obtained using external irradiation however have been decidedly mixed. The first study of external radiation in coronary vessels was carried out by Schwartz at the Mayo Clinic who tested doses of 4 and 8 Gy delivered by an orthovoltage unit to stented pig coronary arteries.²¹ Morphometric analysis carried out four weeks later revealed poorer results in the irradiated animals compared to the controls with the highest dose group faring the worst. This study has been criticized on the basis of magnitude of vessel injury, the use of orthovoltage x-rays and the relatively low doses of radiation which were tested. Due to marked overexpansion of the stent in this study it might be that there is a continuous injury stimulus and the application of radiation at a

single point in time would be relatively ineffective. In addition irradiation of a metallic stent with orthovoltage x-rays is likely to be associated with local areas of high dosage due to electronic disequilibrium. At Emory we circumvented these concerns by using doses of megavoltage x-rays (14 Gy) found effective in endovascular studies following balloon injury.^{22, 23} When 14 Gy was administered to the whole heart immediately before, after or 2 days following balloon injury we observed reduced neointima formation compared with controls but the lumens were smaller due to negative remodeling (contracture) of the vessel. Recent studies performed in our laboratories using 21 Gy external after either angioplasty or stenting showed a profound and consistent suppression of neointima formation and maintenance of the lumen area. **(Table 1)** The lack of benefit seen with 14 Gy external vs 14 Gy endovascular suggest either that large volume irradiation requires larger doses or it is not the minimum dose delivered to the vessel wall which is critical in determining the outcome. Studies of 21 and 14 Gy external radiation treatment have shown focal myocardial necrosis, an observation, which we never made with endovascular irradiation at any dose. To reduce the likelihood of significant effects on the myocardium from even higher doses of external radiation therapy (21 Gy) will require very sophisticated treatment techniques. Whether conformal therapies can be applied to small, moving targets such as the coronary vessels remains to be determined.

b. Catheter Based Irradiation Studies

In contrast to the mixed results from external beam irradiation, numerous investigators have shown consistent benefit of endovascular irradiation on neointima formation. At least three groups have documented similar results in the porcine coronary

model of restenosis, using ^{192}Ir at roughly comparable doses. Wiedermann and co-workers found suppression of neointima 4 weeks after angioplasty when 20 Gy was delivered at a radial depth of 1.5 mm just before arterial injury.²⁴ These same researchers demonstrated a persistence of this effect in arteries harvested at 6 months.²⁵ Similarly, our group at Emory demonstrated profound suppression of neointima using ^{192}Ir with a dose-response effect in vessels treated with 3.5, 7, and 14 Gy at a radial depth of 2 mm, and continued benefit at 6 months in arteries treated with 7 and 14 Gy.²⁶ Mazur and colleagues used a ^{192}Ir high dose rate afterloader and found that 10-25 Gy at 1.5 mm inhibited the 4-week post-injury loss of lumen diameter and suppressed intimal thickening in the left circumflex and left anterior descending coronary arteries, but had no effect in the right coronary artery.²⁷ Our group at Emory performed a separate series of experiments showing that radiation was just as valuable an adjunct to stenting as it was to PTCA²⁸

Because of concerns about the prolonged treatment times and radiation safety problems associated with ^{192}Ir , a number of authors have investigated the potential use of β -emitting isotopes (^{90}Y , $^{90}\text{Sr}/\text{Y}$, and ^{186}Re) in restenosis prevention. At Emory we examined the use of stainless steel-encapsulated seeds containing $^{90}\text{Sr}/\text{Y}$. For 7 and 14 Gy at 2 mm depth we observed a similar effect on neointima formation as with $^{192}\text{Iridium}$.²⁹ Because of the more rapid dose rate of the beta emitter we were able to examine doses of up to 56 Gy and observed maximal suppression with 28 Gy. More recently Robinson has reported on the results of a β -emitting ^{186}Re liquid-filled balloon catheter in the same animal model of restenosis.³⁰ This system has the advantage of allowing the delivery of a very homogeneous dose to the luminal surface. Doses of 15, 20 and 30 Gy were targeted

at 0.5 mm from the balloon-lumen interface. Interestingly positive results were observed with 20 and 30 Gy but not with 15 Gy as one would have expected from the results of sealed source therapy. The reasons for this discrepancy are conjectural but the possibility of local hypoxia as a result of the inflated balloon catheter must be considered a prime suspect.

The effect of endovascular irradiation in a repeat-injury model of restenosis has also been evaluated.³¹ This model may be more analogous to clinical restenosis since a lesion is initially formed by the first balloon injury; 4 weeks later a second balloon angioplasty is applied, at which time brachytherapy is performed. In this model we observed that there was no morphologically apparent effect on the lesion created by the first injury, but the second 'wave' of hyperplasia was inhibited, resulting in a significantly smaller total intima. From these animal studies there is no reason to believe that radiation will have any effect on an established stenosis but simply prevents an overexuberant healing response associated with balloon injury or stent implantation. Although many different studies have shown endovascular brachytherapy to be effective in the short term in preventing renarrowing the results at 6 months have been decidedly mixed. Dr. Raizner and his colleagues from Baylor have shown that a significant component of late lumen loss following treatment to be due to thrombosis. This is felt to be due to delayed re-endothelialization and hopefully will be effectively treated by prolonged antiplatelet therapy.

c. Radioactive Stent Studies

Because a stent already deals with two of the major mechanisms of restenosis the idea of adding radiation to the fabric of the stent has considerable attractiveness. The first evaluation of a radioactive stent comes from Hehrlein and his colleagues from Heidelberg. They took stainless steel stents (Palmaz-Schatz stents) and made them radioactive in a nuclear reactor.³² The stents were highly effective at inhibiting neointima formation but might be problematic for permanent implantation as some of the isotopes created have very long half-lives. Consequently, this same group of researchers and others investigated the effects of stents implanted with radioactive phosphorous (³²P)^{33,34} Subsequently, this stent was tested in pig coronary arteries at various levels of radioactivity. Curiously, it was found that low-activity (0.15- to 0.5- μ Ci) and high-activity (3.0- to 23.0- μ Ci) stents inhibited neointima formation compared to control non-radioactive stents, but those of intermediate activity (1.0- μ Ci) had nearly twice as much neointima³⁵. The authors speculated that either delayed endothelialization or a stochastic effect on extracellular matrix production might be responsible for this puzzling finding. Although the initial results appeared favorable for this form of therapy 6 month follow-up has shown poorer results in the irradiated animals compared to controls, with the highest dose groups doing worse than the lower dose groups.³⁶ It may be that the prolonged delivery of radiation in this application results in very different results than the acute application of radiation.

IV. Clinical Trials of Intracoronary Radiation Therapy

The benefits of intracoronary radiation therapy were just barely established before clinical investigation of this modality was initiated. In **Tables 2, 3 and 4** I have summarized the status of the clinical trials that are planned and underway in the coronary vasculature. In the following sections I would like to focus on the trials in which results have been presented/published.

a. Clinical Trials of Catheter Based Gamma Irradiation

The first reported use of intracoronary radiation therapy to prevent restenosis in humans was from Condado and his colleagues in Caracas, Venezuela.³⁷ This study, which was initiated in 1994 involved the manual delivery of a thin profile (0.014 or 0.018") 30-mm long, ¹⁹²Iridium wire. 22 lesions in 21 patients were treated and a dose of 20-25 Gy was prescribed at 1.5 mm from the center of the source. Two of these patients had a subacute occlusion and an additional patient was found to have a pseudoaneurysm at the treatment site 60 days following ICRT. The initial 6 month angiographic follow-up revealed a dichotomous restenosis rate of 28% and a late loss index of 19%. Continued follow-up of these patients has revealed a durable effect of treatment. This study demonstrated the feasibility of ICRT with a reduction in late loss over what one would normally expect following balloon angioplasty. These patients have been followed now three years following treatment with no observable late effects from the radiation treatment. Despite the initial promising results, investigation of this approach was halted until a remote afterloading system was developed. The SCRIPPS trial was carried out at The Scripps Clinic under the direction of Drs. Paul Tierstein and

Vincent Massullo.³⁸ In this study, patients with restenosis, either following balloon angioplasty or stenting, were randomized to receive radiation or placebo treatment following standard management of the stenosis. This intervention included a stent for patients who had not been previously stented. The radiation delivery system consisted of a variable length source train of ¹⁹²Iridium seeds inserted manually into a 4 French perfusion catheter. The dose prescription was based on Intravascular Ultrasound Images through the angioplastied segment. The dose was calculated such that 8 Gy was delivered to the leading edge of the media as long as the no portion of the vessel wall received more than 30 Gy. 55 patients were randomized on the study before it was halted due to differences in the outcomes in the treatment groups. 29 patients received radiation with an average minimum dose of 7.3 Gy and an average maximum dose of 26.5 Gy. Baseline characteristics of the two groups were closely balanced, as were procedural success rates. The results of this landmark study are summarized in **Table 5**. At 6 months follow-up angiographic restenosis rate was 53.6% in the control group and 16.7% in the irradiated group. This represented a 69% reduction from radiation treatment. The Late Loss Index was 12% in the treated vessels versus 60% in the controls representing an 80 % reduction by the treatment. Similar results were confirmed on the basis of IVUS with an increase of tissue within the stent of 45.1 mm³ in the controls versus 15.5 mm³ in the treated group. Composite clinical end-points of MI, death and target vessel revascularization were similarly reduced compared to the controls. The results of this trial have been updated at two years and the effect of the therapy appears to be durable although there were some cases with late renarrowing. There was no evident long-term injury. Subset analysis has been reported on these patients and

although subject to criticism on the basis of limited patient numbers it was shown that larger vessels, vein grafts and reduced doses of radiation were all associated with a lack of benefit in this study. When the data was analyzed it was found that radiation was slightly less effective at reducing restenosis when one examined the stent and borders compared with the stent alone. As a result of this observation the investigators have made a conscious effort to irradiate beyond the margin of the stented segment.

This important single institution study was developed into a multicenter, double blind randomized trial (Gamma I Trial) under the sponsorship of Cordis Vascular. This trial randomized 252 patients with in-stent restenosis to the same dosing scheme as used in the SCRIPPS Trial or placebo therapy. This trial reported a 58% reduction in restenosis frequency within the stent and a slightly lower (43%) reduction in restenosis frequency within the lesion. The results were significantly better for the shorter lesions treated with 6 and 10 seeds compared to the longer lesions (treated with 14 seeds). No difference in 30 day morbidity rates were noted between the control and treated groups.

Dr. Waksman and his colleagues at the Washington Heart Center have developed three in-house studies using gamma radiation in the management of in-stent restenosis. The original WRIST (Washington Radiation for In-Stent Restenosis Trial) study has randomized 130 patients with in-stent restenosis in native coronary vessels (100) or saphenous vein grafts (30) to placebo or radiation therapy. This study used a simplified dosing scheme with 15 Gy being prescribed at 2 mm from the center of the source. The 6 month angiographic follow-up was reported recently at the American Heart Association meeting and radiation was every bit as beneficial for these patients as it was in the SCRIPPS trial. The restenosis rate was 58 % in the placebo group and 19% in the

control group (a 67% reduction). This benefit was seen in both native coronary vessels and saphenous vein grafts. The WRIST SVG is still enrolling patients with in-stent restenosis within a saphenous vein graft; WRIST LONG is randomizing patients with 36-80 mm length lesions. One new observation from the WRIST trial has been the concept of instant restenosis. IVUS images carried out following vascular brachytherapy have revealed prolapse of tissue within the lumen of the vessel, which was not found on the images prior to therapy. This observation may have important implications regarding the need to debulk in-stent restenosis rather than simply ballooning it.

All of the above trials have not employed any mechanism to actively center the source within the vessel lumen. The 0.014" Iridium wire system originally tested by Condado has been developed by US Surgical into a clinical device incorporating a manual afterloader and a balloon-centering device. The ARTISTIC Trial for in-stent restenosis and the ARREST Trial (post PTCA and provisional stenting) are currently enrolling patients in the evaluation of this approach.

b. Clinical Trials of Catheter Based Beta Irradiation

Verin and his colleagues from Geneva reported the first feasibility study of beta radiation following angioplasty of stenotic lesions in native coronary vessels.³⁹ In this study 18 Gy was delivered to the luminal surface with a 29 mm ⁹⁰Y coil inserted into a closed end segmented balloon catheter following PTCA. Due to decay of the source (T_{1/2}=64 hours) the treatment time was variable but averaged 6-7 minutes. Because of ischemia, fractionation of the dose was necessary in 4 of the original 15 patients studied. At 6 month follow-up the restenosis rate was 6/15 or 40% with four patients (27%) required target lesion revascularization. The Late Loss Index was 50% which is what is

within the range generally expected with PTCA alone. Because of the concern that this less than favorable result might have been related to the dose delivered to the vessel a dose-finding study has been initiated. This will test doses of 9, 18 and 32 Gy delivered to the luminal surface. Use of this same system was piloted by Waksman and his colleagues at the Washington Heart Center. Between May and October of 1998 49 patients were enrolled in this trial which had the same inclusion and exclusion criteria as the original WRIST trial. A dose of 209.6 Gy was delivered at 1 mm from the balloon lumen interface. Because of the prolonged dwell times 21% required fractionation of the dose and approximately 1/3 of the patients had sequential positioning of the source to achieve an adequate treatment length. This trial showed almost exactly the same results as the radiation treatment arm of the WRIST trial with a restenosis rate of 16% in the beta arm and 14% in the gamma arm.

The BERT (Beta Energy Restenosis Trial) Trial represented the first trial of vascular radiotherapy approved by the FDA.⁴⁰ In this phase I-II study, 23 patients were enrolled at Emory University and Brown University to test the feasibility and safety of the administration of three different doses of radiation (12, 14 and 16 Gy) using a source train of ⁹⁰Sr/Y. The source train was contained within a portable transfer device from which the sources were delivered hydraulically to the treatment site within an over-the-wire delivery catheter. (Novoste Corporation, Norcross, GA) **Figure 1** shows a representative case from this study. Following completion of the initial 23 patients in the United States an additional sixty patients were treated on the same protocol at the Montreal Heart Institute and the Thoraxcenter in Rotterdam. The study was designed with the same entry criteria and core laboratory as the Lovastatin Restenosis Trial

permitting a limited assessment of the efficacy of the treatment. 6-month follow-up of the first 64 patients enrolled on the trial revealed a substantially lower restenosis rate and late loss index than expected. (**Table 6**) Additional observations from this trial include evidence of a dose response relationship and reduced late loss index seen in smaller vessels. (**FIGURES 2 AND 3**) The cohort of patients treated in Montreal and Rotterdam underwent IVUS at the time of treatment and at 6 month follow-up. From the Montreal cohort we observed that some dissections did not heal normally following vascular radiation and there was some thinning of the vessel wall on follow-up. (**Table 7**) No frank aneurysms were seen however. In July 1997 the BETACATH (Beta Energy to Address Coronary Atherosclerosis) Trial was opened as a follow-up to the BERT trial using the Novoste BETACATH system. This triple-masked study will enroll 1100 patients with restenosis or stenosis in native coronary vessels. Following initial balloon angioplasty those patients who achieve a stent-like result (< 30% residual stenosis and no major dissection) will be randomized to receive radiation or placebo. If the angioplasty result is not stent-like those patients will receive brachytherapy prior to stent implantation. The dose of radiation in the smaller vessels (2.5 to 3.3 mm) will be 14 Gy at 2 mm; in the larger vessels (3.3-4 mm) it will be 18 Gy. This increase in dose is related to the observed reduced efficacy in larger vessels observed in the BERT Trial. The radiation is administered prior to the stent implantation to circumvent any problems associated with shielding by the stent. Efficacy in this trial will be based on the need for target vessel revascularization at 8 months following intervention. Novoste Corporation has also embarked on a randomized study called the START Trial to test whether beta radiation is a useful adjunct in the management of in-stent restenosis.

Guidant Corporation has developed an afterloading system for vascular brachytherapy using a 27 mm long ^{32}P wire source which is delivered within a helical centering balloon. The initial feasibility study of this device is entitled the PREVENT (Proliferation Reduction with Vascular Energy Trial) Trial which randomized patients between three different doses of radiation (16, 20 and 24 Gy at 1 mm from the balloon/lumen interface) following PTCA or stenting. 6 month angiographic follow-up on 66 of the 72 patients enrolled on the study reveals a marked treatment effect has revealed a marked treatment effect. Only 6% of the irradiated arm had restenosis within the treated area compared to 33% of controls. In this trial a considerable number of patients had restenosis adjacent to the treatment zone suggesting the need for a longer source or the possibility that the balloon centering catheter was creating edge effect. patients whose disease. An additional feasibility study of a partially shielded beta source (^{186}Re) has been developed by Navius and Endosonics Corporation. This device is intended to allow a more homogeneous dose to be delivered to the vessel wall.

A comparison of dose homogeneity delivered to the vessel wall has revealed that liquid source preparations provide some of the most homogeneous doses in catheter based therapies. Two feasibility trials have been organized using radioactive liquid filled balloons: 1. The CURE Trial undertaken at Columbia University under Dr. Judah Weinberger and 2. The RADIANT Trial under the auspices of Vascular Therapies (a branch of US Surgical). Both of these trials utilize ^{188}Re which is milked from a ^{188}W generator. No data on safety or efficacy are yet available.

c. Clinical Trials of Radioactive Stents

The first trial of a ^{32}P impregnated radioactive Palmaz-Schatz stent was undertaken under the direction of Dr. T. Fischell and colleagues and was entitled IRIS (Isostent for Restenosis Intervention Study). This study enrolled 30 patients with de-novo or restenotic lesions of native coronary vessels who were implanted with a stent of mean activity of 0.69 μCi (range 0.5-1.0 μCi). The procedural success rate was 100% but the angiographic restenosis rate at 6 months was 31%, a figure higher than generally expected for patients with these type lesions implanted with non-radioactive stents. Late loss was 0.94 mm for de-novo lesions and 0.70 mm for restenotic lesions suggesting somewhat better results for patients with restenosis. One possible interpretation of this result is that restenotic lesions may be more effectively treated than de novo lesions because the cells that lead to renarrowing following stenting are closer to the luminal surface and the stent. It may be that the very limited dose delivered to the adventitia with a radioactive stent is inadequate for de novo lesions. Results of studies with stents of higher activities (3 and 6 μCi) are pending. The P-S stent has a very irregular structure and is in no way optimal as a carrier to deliver a homogenous dose of radiation to the vessel wall. A new stent (BX Stent) has been developed which may be more optimal for delivering radiation and studies using this stent are currently underway.

V. Conclusions:

Initial feasibility studies and small randomized studies of catheter based therapies for restenosis prevention are promising. The future of radioactive stents are less certain based on the initial feasibility study. Different systems have been developed for clinical use employing different isotopes and means of delivery have led to positive results. Increased sophistication in planning and delivering treatment may lead to further improvement in results. It should be noted that there is a dearth of information from animal studies or human studies beyond two years to tell us whether this large dose per fraction therapy may be associated with significant late effects. In this circumstance it is incumbent on early investigators in the field to practice careful long-term surveillance of their patients. A low incidence of late effects may be tolerated given the significant reduction in clinical events in a substantial portion of the patients irradiated up to date. Endovascular radiation must compete with other alternative therapies for restenosis prevention not only on the basis of efficacy but also on the basis of economics. Given the high cost to the US Health Care system of restenosis (estimated 1-2 billion dollars annually) there appears to be room for the expected costs of vascular radiotherapy. In general radiation has been well accepted by the patients and the cardiology community. The future of brachytherapy looks promising with newer more sophisticated devices coming to the marketplace. Incorporation of treatment planning and increasingly sophisticated treatment techniques may allow further reductions in restenosis. It is my belief that we are in the early phase of the development of vascular brachytherapy much as we were 40 years ago with the first megavoltage treatment machines. Furthermore the

possibility that external radiation treatment may come to be used in the prevention of restenosis is certainly within the realm of possibility. I believe that the Radiation Oncologist brings to this field a unique level of expertise and should continue to play a role in the therapy of vascular disease with radiation over the long-term.

Table 1 Results of external radiation in porcine coronary model of restenosis

	Post Angioplasty			Post Stenting	
	Controls mean	14 Gy	21 Gy	Controls mean	21 Gy
Lumen Area (LA)	1.95±0.66	1.10±0.52	3.68±1.71	4.69±1.87	7.40±1.40
Vessel Area (VA)	4.45±1.05	2.75	5.35±2.46		
Intimal Area (IA)	1.36±0.61	0.793	0.23±0.34	1.36±0.61	0.39±0.60
Maximum Intimal Thickness (MIT)				0.76±0.36	0.12±0.13

Table 2. Clinical Trials of Catheter Based Beta Irradiation

Study	Trial Design	Patients	Radiation Source	Radiation Dose	Outcome
Verin	Phase I/II Post PTCA	15	⁹⁰ Y coil	18 Gy at 0 mm from balloon surface	Feasible; no effect on late loss or restenosis rate
Verin	Phase I/II Post PTCA	160	⁹⁰ Y coil	9, 18.32 Gy to luminal surface	Currently open
Schneider Beta WRIST	Phase I Trial In-stent restenosis	50	⁹⁰ Y coil	20.6 Gy at 0.5 mm from balloon surface	Feasible; similar benefit to gamma radiation
BERT	Phase I/II Post PTCA	83	⁹⁰ Sr/Y seeds	12, 14 or 16 Gy at 2 mm	Feasible; reduced late loss and restenosis rate
BETACATH	Phase III Provisional stenting	1100	⁹⁰ Sr/Y seeds	14 or 18 Gy at 2mm or placebo treatment	Currently open
START	Phase III In-stent restenosis	300	⁹⁰ Sr/Y seeds	16 or 20 Gy at 2 mm or placebo treatment	Currently open
CURE	Phase I/II Post PTCA	60	¹⁸⁸ Re liquid	20 Gy at 0.5 mm from balloon surface	Currently open
Navius/ Endosonics	Phase I/II Post PTCA	25	¹⁸⁸ Re	≤ 30 Gy to EEL based on IVUS	Pending
RADIANT Pilot	Phase I/II Post PTCA	30	¹⁸⁸ Re liquid	24 Gy at 0.5 mm from balloon surface	Currently open
RADIANT Pivotal	Phase III	800	¹⁸⁸ Re liquid	24 Gy at 0.5 mm from balloon surface	Pending
PREVENT	Phase I/II Post PTCA	80	³² P wire	16,20, 24 Gy at 1 mm from balloon surface	Feasible; positive effect of treatment
INHIBIT	Phase III In-stent restenosis	325	³² P wire	Pending above investigations	Pending above investigations

Table 3. Clinical Trials of Catheter Based Gamma Irradiation

Study	Trial Design	Patients	Radiation Source	Radiation Dose	Outcome
Condado	Phase I/II Post PTCA	21	¹⁹² Ir wire	20 or 25 Gy	Feasible; reduced late loss and restenosis rate up to 2 yrs.
ARREST	Phase III; Post PTCA, provisional stenting	700	¹⁹² Ir wire	8 Gy to media max dose≤30 Gy by IVUS	Open
ARTISTIC	Phase III; In-stent restenosis	450	¹⁹² Ir wire	8 Gy to media max dose≤30 Gy by IVUS	Open
SCRIPPS	Phase III In-stent restenosis or post stenting	55	¹⁹² Ir seeds	8 Gy to media max dose≤30 Gy by IVUS	Reduced late loss (index); reduced restenosis rate; reduced Target Vessel revascularization
GAMMA I	Phase III; In-stent restenosis or post stenting	250	¹⁹² Ir seeds	8 Gy to media max dose≤30 Gy by IVUS	Enrollment complete; positive study
WRIST	Phase III In-stent restenosis	100	¹⁹² Ir seeds	15 Gy at 2 mm	Enrollment complete; marked benefit of therapy
WRIST SVG	Phase III; In-stent restenosis of SVG's	120	¹⁹² Ir seeds	15 Gy to 2.4 mm	Open
WRIST Long	Phase III; In-stent restenosis (36-80 mm)	120	¹⁹² Ir seeds	15 Gy to 2 mm	Open

Table 4. Clinical Trials of Radioactive Stents

Study	Trial Design	Patients	Radiation Source	Radiation Dose	Outcome
IRIS IA	Phase I/II; De novo or restenotic lesions	32	³² P; 15 mm Palmaz-Schatz	0.5-1μCi	Feasible; restenosis rate and late loss index higher than expected
IRIS IB	Phase I/II;	25	³² P ; 15 mm Palmaz-Schatz	0.7-1.5μCi	Feasible; results pending
Hehrlein	Phase I/II	15	³² P ; 15 mm Palmaz-Schatz	3μCi	Feasible; results pending
Colombo	Phase I/II		³² P ; 15 mm Palmaz-Schatz	6-8μCi	Feasible; Results pending
Isostent	Phase I/II		³² P ; 15 mm BX Stent	0.7-1.5μCi	Not yet open

Table 5. SCRIPPS Trial Results

	¹⁹² -Iridium	Placebo	p-value
Late Loss Index	60%	12%	0.002
Restenosis (%)	17	54	0.01
Death, MI, TLR	19	62	<0.01

Table 6 Comparison of Late Loss, Late Loss Index and Restenosis Rates in BERT and LRT Trials

	BERT (n=64)	LRT (n=201)
Late Loss (mm)	0.03	0.4
Late Loss Index (%)	-3	43
Restenosis (%)	14	42

Table 7 QCA/IVUS results from Montreal in BERT patients

	Pre	Post	F-U
QCA MLD (mm)	0.76±0.05	2.03±0.06 *	2.05±0.09*
EEM area (mm ²)	12.46±0.87	14.49±0.97*	14.40±0.91*
Lumen area (mm ²)	1.92±0.16	5.96±0.30 *	7.09±0.45* [†]
Wall area (mm ²)	10.55±0.86	8.48±0.79 *	7.35±0.64*

* p < 0.01 vs Pre; † p<0.05 vs Post

Figure 1 Representative Case from BERT Trial

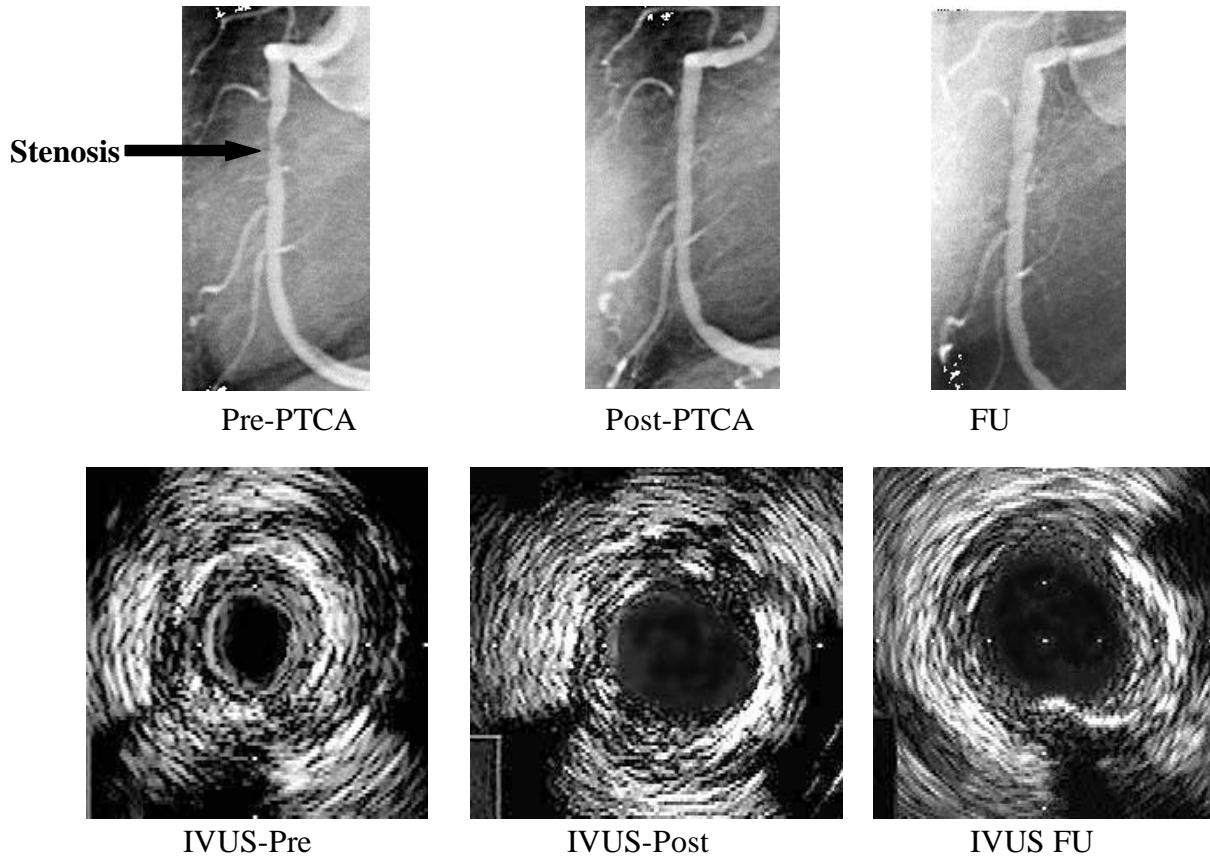


Figure 2 Evidence of Dose Response Relationships in BERT Trial

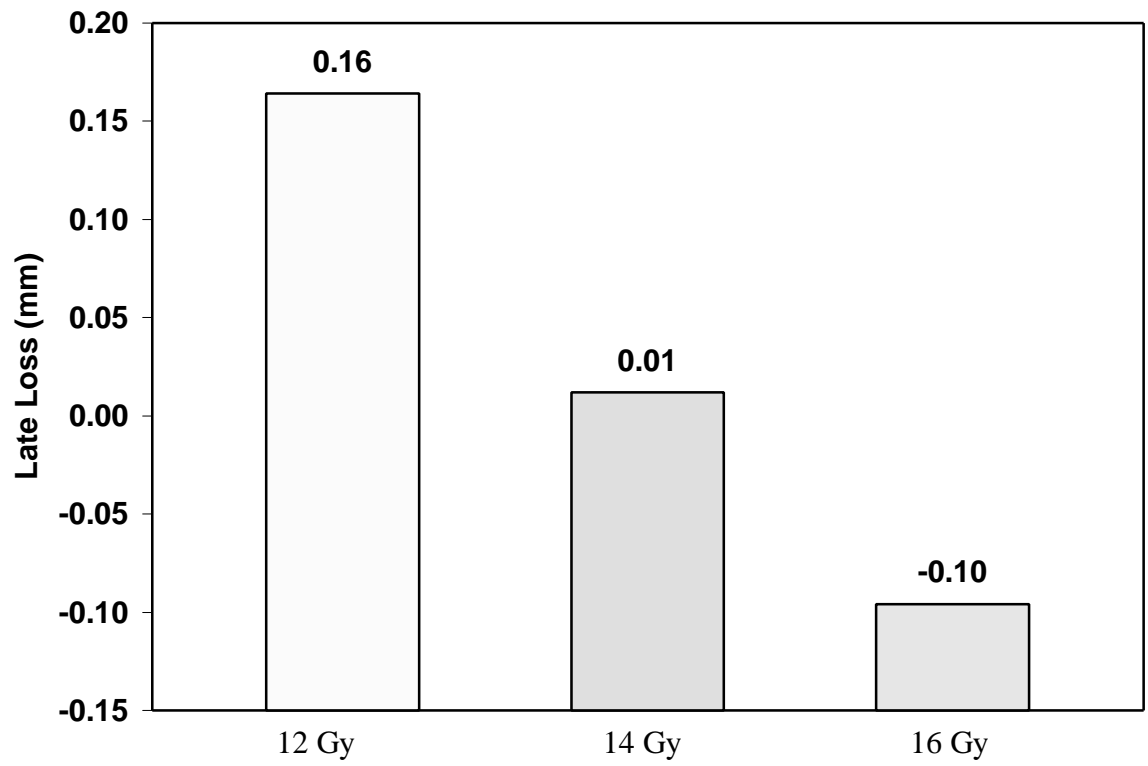
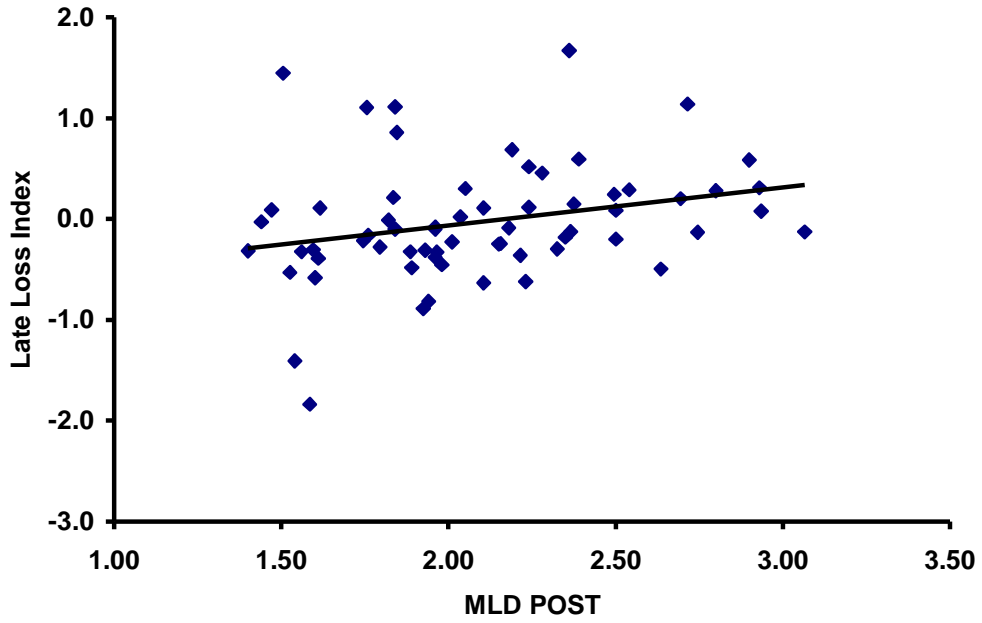


Figure 3 Loss of Effectiveness of Vascular Brachytherapy in Larger Vessels in the BERT Trial



REFERENCES

1. Hillegass WB, Ohman EM, Califf RM. Restenosis: the clinical issues. In Topol EJ, ed., *Textbook of Interventional Cardiology*, 2nd ed vol.1. W.B. Saunders, Inc., Philadelphia, 1994, pp 415-35.
2. Ludbrook PA. Coronary restenosis: its mechanisms and modification - overview. *Coronary Artery Disease* 1993;4:225-28.
3. Klein LW, Rosenblum J. Restenosis after successful percutaneous transluminal coronary angioplasty. *Prog Cardiovasc Dis* 1990;32:365-382.
4. Popma JJ, Califf RM, Topol EJ. Clinical trials of restenosis after coronary angioplasty. *Circulation* 1994;84(3):1426-36.
5. Franklin SM, Faxon DP. Pharmacologic prevention of restenosis: review of the randomized clinical trials. *Coronary Artery Disease* 1993;4:232-42.
6. Weintraub WS, and the LRT Study Group. Lack of effect of lovastatin on restenosis after coronary angioplasty. *N Engl J Med* 1994;331:1331-37.
7. Faxon DP, and the ERA Investigators. Low molecular weight heparin in prevention of restenosis after angioplasty: results of the enoxaparin restenosis (ERA) trial. *Circulation* 1994;90:908-14.
8. Kuntz RE, Gibson M, Nobuyoshi M, Baim DS. Generalized model of restenosis after conventional balloon angioplasty, stenting and directional atherectomy. *J Am Coll Cardiol* 1993;21:15-25.
9. Wong CS, Leon MB, Popma JJ. New device angioplasty: the impact on restenosis. *Coronary Artery Disease* 1993;4:243-53.
10. Serruys PW, De Jaegere P, Kiemenij F, Macaya C, Rutsch W, Heyndrickx G, Emmanuelsson H, Marco J, Legrand V, Materne P, Belardi J, Sigwart U, Colombo A, Goy J, Van Den Heuvel P, Delcan J, Morel M. A comparison of balloon-expandable stent implantation with balloon angioplasty in patients with coronary artery disease. *N Engl J Med* 1994;331:489-95.
11. Fischman DL, Leon MB, Baim DS, Schatz RA, Savage MP, Penn I, Detre K, Veltri L, Ricci D, Nobuyoshi M, Cleman M, Heuser R, Almons D, Tierstein P, Fish D, Colombo A, Brinker J, Moses J, Shakhovich A, Hirshfeld J, Bailey S, Ellis S, Rake R, Goldberg SA. A randomized comparison of coronary stent placement and balloon angioplasty in the treatment of coronary artery disease. *N Engl J Med* 1994;331:496-501.

12. Dussaillant GR, Mintz GS, Pichard AD, Kent KM, Satler LF, Popma JJ, Wong SC, Leon MB. Small stent size and intimal hyperplasia contribute to restenosis: a volumetric intravascular ultrasound analysis. *J Am Coll Cardiol* 1995;26:720-724.
13. Austin GE, Ratliff NB, Hollman J, Tabei S, Phillips DF. Intimal proliferation of smooth muscle cells as an explanation for recurrent coronary artery stenosis after percutaneous transluminal coronary angioplasty. *J Am Coll Cardiol* 1985;6:369-75
14. Essed CE, van den Brand M, Becker AE. Transluminal coronary angioplasty and early restenosis: fibrocellular occlusion after wall laceration. *Br Heart J* 1983;49:393-96.
15. Liu MW, Roubin GS, King SB III. Restenosis after coronary angioplasty: potential biologic determinants and role of intimal hyperplasia. *Circulation* 1989;79:1374-86.
16. Gravanis MB, Roubin GS. Histopathologic phenomena at the site of percutaneous transluminal coronary angioplasty: the problem of restenosis. *Hum Pathol* 1989;20:477-85
17. Fischer-Dzoga K, Dimitrievich GS, Griem ML. Differential radiosensitivity of aortic cells *in vitro*. *Radiat Res* 1984;99:536-46.
18. Rosen E, Goldberg K, Myrick K. Radiation survival properties of cultures vascular smooth muscle cells. *Radiat Res* 1984;100:182-91.
19. Fischer-Dzoga K, Dimitrievich GS, Schaffner T. Effect of hyperplasmic serum and irradiation on wound healing in primary quiescent cultures of vascular cells. *Exp Mol Pathol* 1989;52:1-12.
20. Karas SP, Gravanis MB, Santoian EC, Robinson KA, Anderberg KA, King SB III. Coronary intimal proliferation after balloon injury and stenting in swine: an animal model of restenosis. *J Am Coll Cardiol* 1992;20:467-74.
21. Schwartz RS, Koval TM, Edwards WD, Camrud AR, Bailey KR, Browne K, Vlietstra RE, Holmes DR. Effect of external beam irradiation on neointimal hyperplasia after experimental coronary artery injury. *J Am Coll Cardiol* 1992;19:1106-1113.
22. Styles T, Marijianowski MMH, Robinson KA, Cipolla GD, King SB III, Davis LW, Crocker IR. Effects of external irradiation of the heart on the coronary artery response to balloon angioplasty injury in pigs. *Proceedings from Advances in Cardiovascular Radiation Therapy* 1997; 11.
23. Marijianowski MMH, Styles T, Crocker IR, Waksman R, Cipolla GD, King SB III, Robinson KA. Epicardial artery and myocardial response to irradiation in the pig coronary artery model of balloon angioplasty: comparison of the histopathologic

consequences of endovascular vs. external beam irradiation techniques (abstract). *Proceedings from Advances in Cardiovascular Radiation Therapy* 1997; 10.

24. Wiedermann JG, Marboe C, Schwartz A, Amols H, Weinberger J. Intracoronary irradiation reduces restenosis after balloon angioplasty in a porcine model. *J Am Coll Cardiol* 1994;23:1491-1498.
25. Wiedermann JG, Marboe C, Amols H, Schwartz A, and Weinberger J. Intracoronary irradiation markedly reduces neointimal proliferation after balloon angioplasty in swine: persistent benefit at 6-month follow-up. *J Am Coll Cardiol* 1995;25:1451-1456.
26. Waksman R, Robinson KA, Crocker IR, Gravanis MB, Cipolla GD, King SB III; Endovascular low dose irradiation inhibits neointima formation after coronary artery balloon injury in swine: a possible role for radiation therapy in restenosis prevention. *Circulation* 1995;91:1553-1539.
27. Mazur W, Ali MN, Khan MM, Dabaghi SF, DeFelice CA, Paradis P Jr, Butler EB, Wright AE, Fajardo LF, French BA, Raizner AE. High dose rate intracoronary radiation for inhibition of neointimal formation in the stented and balloon-injured porcine model of restenosis: angiographic, morphometric, and histopathologic analyses. *Int J Radiation Oncology Biol Phys* 1996;36(4):777-788.
28. Waksman R, Robinson KA, Crocker IR, Gravanis MB, Palmer SJ, Wang C, Cipolla GD, King, SB III. Intracoronary radiation prior to stent implantation inhibits neointima formation in stented porcine coronary arteries. *Circulation* 1995;92:1383-1386.
29. Waksman R, Robinson K, Crocker I, Wang C, Gravanis M, Cipolla G, Hillstead R, King, III S. Intracoronary low dose β -irradiation inhibits neointima formation after coronary artery balloon injury in the swine restenosis model. *Circulation* 1995;92:3025-3031.
30. Robinson K, Pipes D, van Bibber R, Ferguson M, Kunz L, Smith E, Mazeika J. Dose-Response Evaluation in Balloon-injured Pig Coronary Arteries of a β -emitting ^{186}Re Liquid-filled Balloon Catheter System for Endovascular Brachytherapy. *Proceedings from Advances in Cardiovascular Radiation Therapy* 1997; 7
31. Waksman R, Robinson KA, Crocker IR, Gravanis MB, Cipolla GD, Seung K, King SB III. Intracoronary radiation decreased the second phase of intimal hyperplasia in a repeat balloon angioplasty model of restenosis. *Int J Radiat Oncol Biol Phys* 1997;39(2):475-480.
32. Hehrlein C, Gollan C, Donges K, Metz J, Riessen R, Gehsenfeld P, Von Hodenberg E, Kubler W. Low-dose radioactive endovascular stents prevent smooth muscle cell proliferation and neointimal hyperplasia in rabbits. *Circulation* 1995;92:1570-1575.

33. Hehrlein C, Stintz M, Kinscherf R, Schlosser K, Huttel E, Friedrich L, Fehsenfeld P, Kubler W. Pure β -particle-emitting stents inhibit neointima formation in rabbits. *Circulation* 1996; 93:641-645.
34. Fischell TA, Kharma BK, Fischell DR, Loges PG, Coffey CW, Duggan DM, Naftilian AJ. Low dose β -particle emission from 'stent' wire results in complete, localized inhibition of smooth muscle cell proliferation. *Circulation* 1994;90:2956-2963.
35. Carter AJ, Laird JR, Bailey LR, Hoopes TG, Farb A, Fischell DR, Fischell RE, Fischell TA, Virmani R. Effects of endovascular radiation from a β -particle-emitting stent in a porcine coronary restenosis model: a dose-response study. *Circulation* 1996;94:2364-2368.
36. Carter AJ, Scott D, Bailey LR, Jones R, Fischell TA, Virmani R. High activity ^{32}P stents promote the development of atherosclerosis at six months in a porcine coronary model. *Circulation*. 1997;96(suppl I):I-607. Abstract.
37. Condado JA, Waksman R, Gurdiel O, Espinosa R, Gonzalez J, Burger B, Villoria G, Acquatella H, Crocker IR, Seung KB, Liprie SF. Long-term angiographic and clinical outcome after percutaneous transluminal coronary angioplasty and intracoronary radiation therapy in humans. *Circulation* 1997; 96(3):727-32
38. Teirstein PS, Massullo V, Jani S, Popma JJ, Mintz GS, Russo RJ, Schatz RA, Guarneri EM, Steuterman S, Morris NB, Leon MB, Tripuraneni P. Catheter-based radiotherapy to inhibit restenosis after coronary stenting. *New England Journal of Medicine* 1997; 336(24):1697-703
39. Verin V, Urban P, Popowski Y, Schwager M, Nouet P, Dorsaz PA, Chatelain P, Kurtz JM, Rutishauser W. Feasibility of intracoronary β -irradiation to reduce restenosis after balloon angioplasty: a clinical pilot study. *Circulation* 1997;95:1138-44.
40. King SB III, Williams DO, Chougule P, Klein JL, Waksman R, Hilstead R, Macdonald J, Anderberg K, Crocker IR. Endovascular Beta-radiation to Reduce Restenosis after Coronary Balloon Angioplasty: Results of the Beta Energy Restenosis Trial (BERT). *Circulation* 1998; 97(20):2025-30

