

ORIGINAL ARTICLE

Evaluation of Myofibroblasts in Oral Squamous Carcinoma: An Immunohistochemical Study

Mohammad Shafi Dar¹, Ahmad Danish Rehan², Jiji George³

¹Lecturer, Department of Oral Pathology, Indira Gandhi Govt Dental College, Jammu, India

²Reader, Department of Oral Pathology, Hazaribag College of Dental Sciences & Hospital, Jharkhand, India

³Professor, Department of Oral Pathology, Babu Banarasi Das College of Dental Sciences, Lucknow, U.P., India

ABSTRACT:

Background: The presence of cancer is followed by some changes that happen in epithelium & the normal stroma and normal stroma becomes a reactive one. Myofibroblasts secrete cytokines and matrix metalloproteases which in turn contribute to the destruction of extracellular matrix and cause tumor growth. Hence; we planned the present study to assess the expression of myofibroblasts in oral squamous cell carcinoma (OSCC) cases. **Methods:** The present study included immunohistochemical assessment of expression of alpha smooth muscle actin (α -SMA) in OSCC cases and 10 normal control were included in the present study. N Immunohistochemical staining of all the OSCC sections and normal controls (NC) was done. Immunostaining was assessed by the evaluation of the staining intensity and percentage of α -SMA-positive cells. Staining index for each group was calculated and compared. All the results were analyzed by SPSS software. **Results:** Staining index of myofibroblasts was positive in all the sections of OSCC and was significantly higher (p - value <0.05) as compared to normal control group. **Conclusions:** Myofibroblasts do play a significant role in epithelial malignant transformation. **Key words:** Alpha-smooth muscle actin, myofibroblast, oral squamous cell carcinoma.

Corresponding author: Dr. Mohammad Shafi Dar, Lecturer, Department of Oral Pathology, Indira Gandhi Govt Dental College, Jammu, India

This article may be cited as: Dar MS, Rehan AD, George J. Evaluation of Myofibroblasts in Oral Squamous Carcinoma: An Immunohistochemical Study. J Adv Med Dent Scie Res 2017;5(12):46-48.

Access this article online	
<p>Quick Response Code</p> 	<p>Website: www.jamdsr.com</p>
	<p>DOI: 10.21276/jamdsr.2017.5.12.14</p>

INTRODUCTION

Squamous cell carcinoma is defined as “a malignant epithelial neoplasm exhibiting squamous differentiation as characterized by the formation of keratin and/or intercellular bridges”.

The presence of cancer is followed by some changes that happen in epithelium & the normal stroma and normal stroma becomes a reactive one.¹⁻⁴ The formation of reactive stroma is associated with the secretion of cytokines such as $\text{tg}\beta$ -1 from cancerous cells that promotes differentiation of fibroblasts into myofibroblasts, increases the number of blood vessels, increases the inflammatory cells, causes desmoplasia, decreases the expression of epithelial markers (cadherins), and increases the expression of mesenchymal markers such as vimentin. Myofibroblasts in turn secrete cytokines and matrix metalloproteases which in turn contribute to the destruction of extracellular matrix and cause tumor growth.⁵⁻⁸ Hence; we planned the present study to assess the expression of myofibroblasts in oral squamous cell carcinoma (OSCC) cases.

MATERIALS AND METHODS

The present study was conducted in the Lucknow in 2013 and included immunohistochemical assessment of expression of alpha smooth muscle actin (α -SMA) in OSCC cases. A total of 10 OSCC cases and 10 normal control were included in the present study. Normal control included tissues taken while performing frenectomy procedure. H and E staining was done for confirming the diagnosis of OSCCC. Immunohistochemical staining of all the OSCC sections and normal controls (NC) was done. Immunostaining was assessed by the evaluation of the staining intensity and percentage of α -sma-positive cells, according to the method used by etemad-moghadam et al.⁵ The percentage of immuno-positive cells in the non-inflammatory and non-endothelial stromal cells in the subepithelial connective tissue of osmf and non – endothelial and non – inflammatory cells at the tumour invasive front of oscc in 10 high power fields (hpf) and average percentage per hpf was calculated and recorded as : 0% = no positive cells, 1% = 1–25% positive cells, 2% = 26–50% positive cells, and 3% = 51–100% positive cells. Staining intensity (s.i) was evaluated as: 0% = when there was no staining; 1% = in parts where positivity was observed only at a

magnification of x 400; 2% = in cases where the staining was obvious at x 100, but not at x 40; and 3% = in fields where immuno-positive cells were seen even at x 40. Multiplication of the percentage and intensity scores comprised the staining index (i) of each specimen. This index was classified as: zero = 0, low = 1, 2, moderate = 3, 4 and high = 6–9. Staining index for each group was calculated and compared. All the results were analyzed by SPSS software. Chi- square test and student t test were used for assessment of level of significance. P- value of less than 0.05 was taken a significant.

RESULTS

In the present study, we observed that staining index of myofibroblasts was positive in all the sections of OSCC and was significantly higher (p – value <0.05) as compared to normal control group.

DISCUSSION

Myofibroblasts may be defined morphologically and immunologically through identification of expressed cytoskeletal proteins. The simplest definition of a myofibroblast is that they are smooth-muscle-like fibroblasts. Myofibroblasts may well represent an intermediate state between fibroblasts and smooth muscle cells.^{9- 12} OSCC, like other epithelial malignancies is characterized by abnormal cellular division, invasion of malignant epithelial cells in the connective tissue and specifically, aberrant keratinization in the form of keratin pearls. Keratin production by the cells is the symbol of their functional differentiation.^{13- 15} Hence; we planned the present study to assess the expression of myofibroblasts in oral squamous cell carcinoma (OSCC) cases.

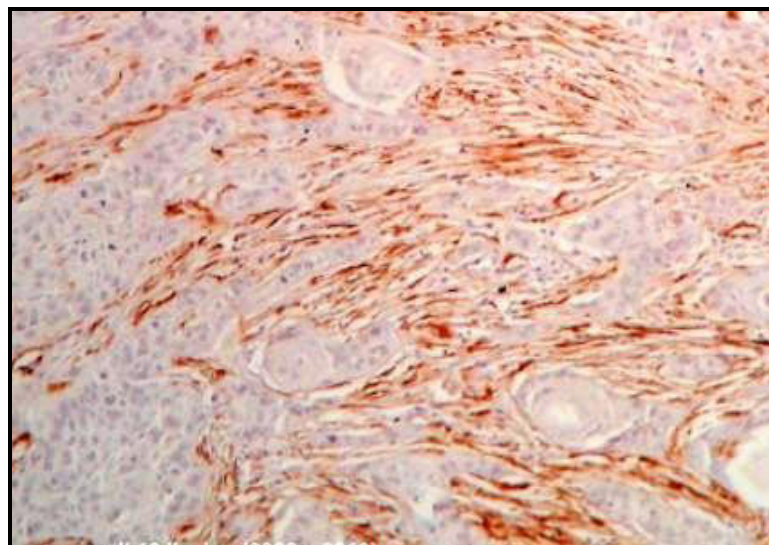
In the present study, we observed significant difference in the staining intensity of α-SMA in OSCC specimens in comparison to NC specimens. These findings may suggest that the formation and differentiation of myofibroblasts is induced somewhere in the invasive stage of OSCC, and further increase in severity and differentiation would not affect the number of these cells. Our results were in correlation with the results obtained by previous authors. Gandhi P et al evaluated and compared the presence of myofibroblasts in normal mucosa, different grades of OSMF, and oral squamous cell carcinoma (OSCC). The present in vitro cross-sectional descriptive study sample consisted of three groups, including 40 OSCCs, 40 OSMF, and 10 sections of normal oral epithelium taken as control group. Alpha-smooth muscle actin was used to identify myofibroblasts using immunohistochemical technique. P < 0.05 was taken as statistically significant. The presence of myofibroblasts was significantly higher in OSMF cases when compared with normal epithelium specimens. The presence of myofibroblasts was significantly higher in OSCC compared to OSMF cases. A significant difference was not observed between the different grades of OSCC. These findings favored the possibility that OSMF actually represents an abnormal healing process in response irritation caused by areca nut. A significant increase in myofibroblasts in OSCC as compared to OSMF also highlights the possible role it may play in the malignant transformation of OSMF.⁴ Gupta K et al evaluated and compared the distribution of MFs using alpha smooth muscle actin (α-SMA) in OL, OSMF, and various histopathological grades OSCC.

Table 1: Comparison of staining intensity between OSCC and normal control

Groups	No. of specimens	Percentage of myofibroblasts score (a)		Staining intensity score (b)		Staining index score (i) i = a x b	
		T - value	P – value	T - value	P - value	T – value	P - value
OSCC vs NC	20	7.558	< 0.05 (s)	10.225	< 0.05 (s)	11.245	< 0.05 (s)

S = significant

Figure 1: Photograph showing positive staining of alpha SMA in OSCC sections.



Sixty formalin-fixed paraffin-embedded tissue blocks consisting of histopathologically diagnosed cases of normal mucosa (n = 10), OL (n = 14) hyperkeratosis with various grades of dysplasia, OSMF (n = 11), and OSCC (n = 25) were subjected to immunohistochemistry using α -SMA antibody for detection of MFs. MFs were not detected in normal oral mucosa. On comparison of frequency of mean scores in OL, OSMF, and OSCC the values were 0.6 ± 0.2 (0-2), 1.2 ± 0.68 (1-2), and 2.6 ± 1.34 (0-4), respectively. The results were statistically significant ($P < 0.001$). These findings were suggestive of role of MFs with the creation of a permissive environment for tumor invasion in OSCC.¹⁶ de-Assis EM et al evaluated the presence of stromal myofibroblasts in OL and OSCC. Differences in the presence of myofibroblasts among OL with distinct grades of epithelial dysplasia as well as between histologically high- and low-invasive OSCC were also assessed. A total of 30 OL and 41 OSCC from archival formalin-fixed, paraffin-embedded specimens were evaluated. 10 samples of normal oral mucosa were used as a control. Myofibroblasts were identified by immunohistochemical detection of alpha smooth muscle actin and its presence was classified as negative, scanty or abundant. Myofibroblasts were not detected in normal oral mucosa and OL, whatever its histological grade. In OSCC, the presence of stromal myofibroblasts was classified as negative in 11 (26.8%), scanty in 15 (36.6%), and abundant in 15 samples (36.6%). The presence of stromal myofibroblasts was statistically higher in high-invasive OSCC than in low-invasive OSCC ($p < 0.05$). These findings suggested that myofibroblasts are associated with the creation of a permissive environment for tumor invasion in OSCC.¹⁷

CONCLUSION

From the above results, the authors concluded that myofibroblasts do play a significant role in epithelial malignant transformation. However; future studies are recommended.

REFERENCES

1. Angadi PV, Rao SS. Areca nut in pathogenesis of oral submucous fibrosis: revisited. *Oral maxillofac surg* (2011) 15:1-9
2. Rajendra R, shivapathasundharam B. (editors), shafer's textbook of oral pathology; 7th edition, elseviers, 2006
3. Seifi S, Shafaei S et al. Myofibroblast stromal presence and distribution in squamous epithelial carcinomas, oral dysplasia and hyperkeratosis. *Asian pac j cancer prev*. 2010;11(2):359-64.
4. Gandhi P, Prasad UC. Evaluation of myofibroblasts in oral submucous fibrosis and oral squamous cell carcinoma: the pathogenesis and correlation. *Dent res j (isfahan)*. 2017 sep- oct;14(5):314-320.
5. Kellermann MG, Sobral M, Da Silva SD et al. Mutual paracrine effects of oral squamous cell carcinoma cells and normal oral fibroblasts: induction of fibroblast to myofibroblast transdifferentiation and modulation of tumor cell proliferation. *Oral oncol*. 2008 may;44(5):509-17.
6. Rockey DC, Weymouth N, Shi Z. Smooth muscle α actin (acta2) and myofibroblast function during hepatic wound healing. *Plos one*. 2013; 8(10): e77166.
7. Powell DW, Mifflin RC et al. Myofibroblasts. I. Paracrine cells important in health and disease. *Am. J. Physiol*. 277 (cell physiol. 46): c1-c19, 1999
8. Rockey DC, Weymouth N, Shi Z. Smooth muscle α actin (acta2) and myofibroblast function during hepatic wound healing. *Plos one*. 2013 oct 29;8(10):e77166
9. Frank Strutz. The great escape-myofibroblasts in fibrosis and the immune system. *Nephrol. Dial. Transplant*. (2008)23 (8): 2477-2479.
10. Pallavi D. Shirol, Dayanand D. Shirol. Myofibroblasts in health and disease. *Int J Oral Maxillofac Pathol* 2012;3(1):23-27
11. Majno G, Gabbiani G, Hirschel BJ, Ryan GB, Statkov PR. Contraction of granulation tissue in vitro: similarity to smooth muscle. *Science*. 1971 aug 6;173(3996):548-50.
12. Zhang HY, Phan SH. Inhibition of myofibroblast apoptosis by transforming growth factor beta(1). *Am J Respir Cell Mol Biol*. 1999 Dec;21(6):658-65.
13. Vaughan MB, Howard EW, Tomasek JJ. Transforming growth factor-beta1 promotes the morphological and functional differentiation of the myofibroblast. *Exp Cell Res*. 2000 May 25;257(1):180-9.
14. Folger PA, Zekaria D, Grotendorst G, Masur SK. Transforming growth factor-beta-stimulated connective tissue growth factor expression during corneal myofibroblast differentiation. *Invest Ophthalmol Vis Sci*. 2001 Oct;42(11):2534-41.
15. Cogan JG, Subramanian SV, Polikandriotis JA, Kelm RJ Jr, Strauch AR. Vascular smooth muscle alpha-actin gene transcription during myofibroblast differentiation requires Sp1/3 protein binding proximal to the MCAT enhancer. *J Biol Chem*. 2002 Sep 27;277(39):36433-42.
16. Malmström J, Lindberg H, Lindberg C, Bratt C, Wieslander E, Delander EL et al. Transforming growth factor-beta 1 specifically induce proteins involved in the myofibroblast contractile apparatus. *Mol Cell Proteomics*. 2004 May;3(5):466-77.
17. Gupta K1, Metgud R, Gupta J. Evaluation of stromal myofibroblasts in oral leukoplakia, oral submucous fibrosis, and oral squamous cell carcinoma--an immunohistochemical study. *J Cancer Res Ther*. 2015 Oct-Dec;11(4):893-8. doi: 10.4103/0973-1482.147700.
18. de-Assis EM1, Pimenta LG, Costa-e-Silva E, Souza PE, Horta MC. Stromal myofibroblasts in oral leukoplakia and oral squamous cell carcinoma. *Med Oral Patol Oral Cir Bucal*. 2012 Sep 1;17(5):e733-8.

Source of support: Nil

Conflict of interest: None declared

This work is licensed under CC BY: *Creative Commons Attribution 3.0 License*.

Arp2/3 Complex Is Expressed in Oral Squamous Cell Carcinoma: An Immunohistochemical Study of 88 Cases. Marina P. Georgopoulou. 1*. This is a retrospective immunohistochemical study of 88 cases of oral carcinoma retrieved from the files of the Laboratory of Histology and Embryology, Faculty of Medicine, during the years 2005-2008 (approval no. 5171). Statistical evaluation was performed using Fisher's test to compare the positive or negative (binary) expression of Arp2 and Arp3 with the type and differentiation of OSCC (factor variable) forming consistency tables and we investigated as well the correlation between the expression of Arp2 and Arp3. 3. Results. Expression of Myofibroblasts in Oral Squamous Cell Carcinoma: An Immunohistochemical Study. Published in. *Journal of Contemporary Dental Practice*, October 2016. Malignant epithelium might induce the adjacent stromal tissue to produce myofibroblasts. These specialized cells may be utilized as therapeutic targets for the treatment of OSCC. Proliferation of myofibroblasts may be used as a stromal marker of premalignancy and malignancy. View on publisher site Alert me about new mentions. Twitter Demographics. Evaluation of myofibroblasts in superficial and deep layers of oral squamous cell carcinoma; an immunohistochemical study. Seyed Hosein Tabatabaei, Laleh Maleki, Arezoo Amirkafi. Published: 6 April 2019. by International Society for Phytocosmetic Sciences. in *Immunopathologia Persa*. *Immunopathologia Persa*, Volume 5; doi:10.15171/ipp.2019.12. Publisher Website. Google Scholar.